
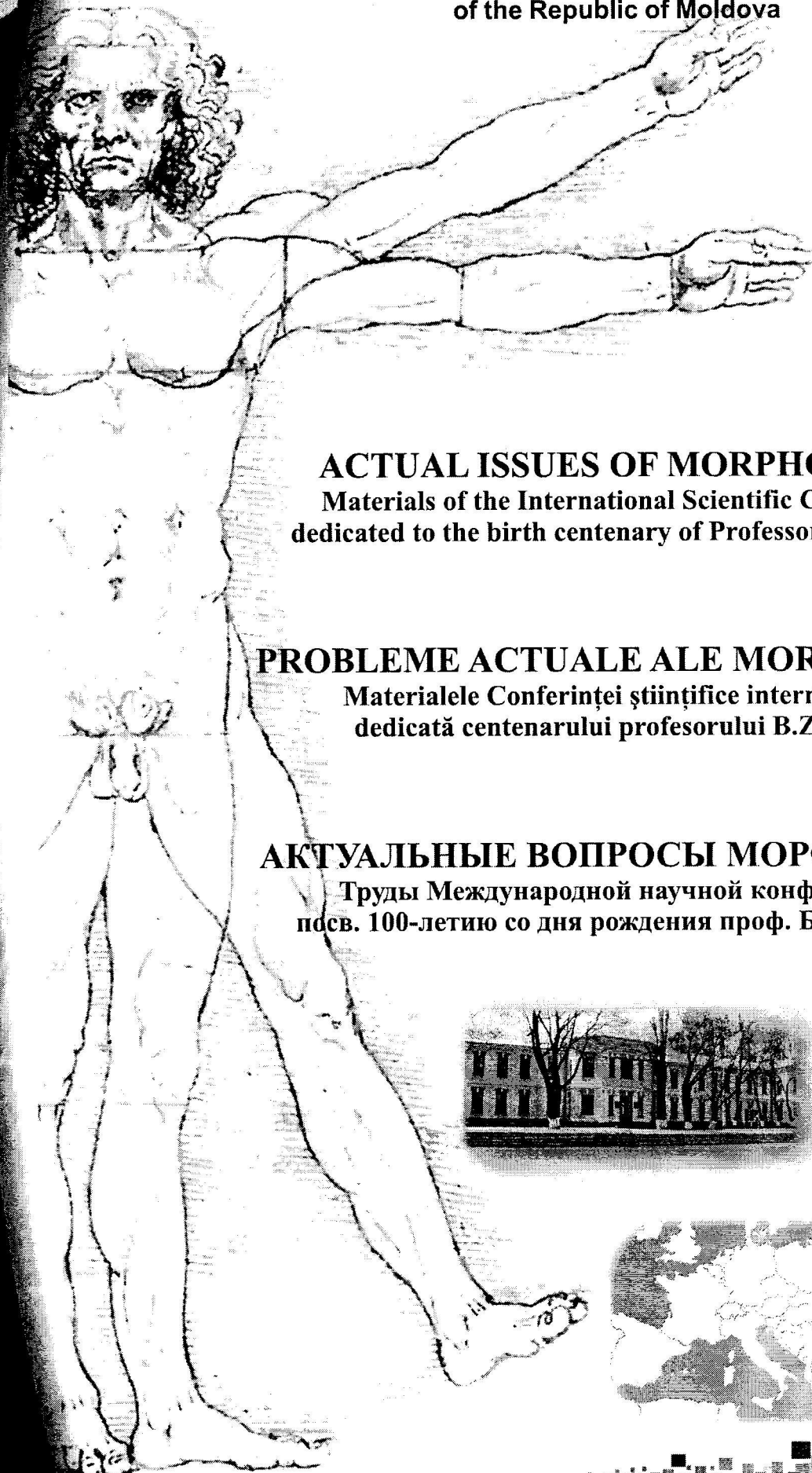


CONTENTS • CUPRINS • СОДЕРЖАНИЕ

Батыр Д. Г., Винченко Г. В., Кердиваренко Н. В. Б. З. Перлин – жизнь и деятельность	8
Кердиваренко Н. В. Б. З. Перлин и подготовка научно-педагогических кадров	13
Винченко Г. В., Катеренюк И. М., Штефанец М. И. Музей кафедры анатомии человека Государственного Университета Медицины и Фармации им. Николая Тестемицану	18
Халитова В. И., Френкель (Мякушева) Н., Штейнберг М. И., Белугина В. А., Папук-Коваль О. Т., Лещенко Н. В., Рощина-Кожекорова О. Н. Воспоминания о профессоре Борисе Зиновьевиче Перлине	27
Catereniuc I., Lupașcu T., Ștefanec M., Batâr D. Catedra Anatomia omului a USMF „Nicolae Testemițanu”. Etapе de dezvoltare, activitate științifică, perspective	33
Akhtemiychuk Yu., Pronyaev D. V. Anatomical peculiarities of the iliocecal junction at the prenatal period of ontogenesis	45
Andrieș V., Catereniuc I., Lupașcu T., Globa L. Aspecte noi asupra inervației bronhiilor și a plămânilor	49
Andrieș V., Catereniuc I., Lupașcu T., Globa L. Inervația capsulei și ligamentelor articulației coxofemorale în norma și modificările ei în coxita tuberculoasă	56
Andronic S. Întrebări referitoare la clasificarea degenerescenței maculare legate de vârstă	62
Arensburg B., Heiman A., Wolf M., Belkin V. The impact of global climatic variations upon middle ear ossicles dimensions	68
Arnăuț C., Căuș C., Ghinjuț C. Unele aspecte morfo-histochimice ale genezei componentelor structurale a substanței intercelulare din adventicea aortei umane	74
Arnăuț C., Căuș C., Ghinjuț C. Unele date preventive, referitoare la microcirculația sanguino-limfatică din peretele aortei umane în ontogeneză și rolul ei în patogeneza aterosclerozei	79
Batâr D., Babuci A. Structura elementelor nervoase ale fasciilor pectorale la nivel mezoscopic	84
Belic O. Vasele lienale: aspecte structurale și topografice	88
Bendelic A., Catereniuc I. Venele superficiale și cele perforante ale membrului inferior – morfologie, terminologie și importanță clinică	100
Catereniuc I., Guzun G., Rotaru V., Chiroșca L., Turchin R., Catereniuc T. Rolul acupuncturii în medicina contemporană (Revista literaturii)	105
Certan G., Catereniuc I., Babuci A., Zorin Z., Anghelii R., Globa L. Cu privire la inervația venei cave superioare	109
Covaliu V. I., Covaliu V. B. Plexul nervos cavo-hepatic – componenta extraportală a aparatului nervos al ficatului	112
Didoruc S. Inervația extraorganică a glandelor mamare la cățea	118
Enciu V. Dezvoltarea și formarea surselor de inervație și a rețelei nervoase a periostului oaselor autopodiilor la bovine	124
Fetisov S. O., Semenov S. N., Alexeeva N. T. Reactive and destructive reactions of dorsal root ganglion neurons in the simulation of deep skin wounds healing at different rates	131
Hacina T. Corpi adipoși periaortici și pericardiaci: aspecte actuale	135
Kolesnyk V. V., Olijnyk I. Yu. The features of research of the cerebrum of fetuses and newborns	140
Kvaratskheliya A. G., Semyonov S. N., Fetisov S. O., Voronezh N. N. Morphofunctional changes in the structure of rats' adrenal glands cortex zones by alcohol intoxication and the effect of antioxidant	143
Lisii C., Sainsus I., Nacu V. Acțiunea câmpului electromagnetic pulsant de frecvență joasă asupra proliferării și morfologiei celulelor stem mezenchimale	147
Lopotencu E. Иннервация надкостницы костей кисти	151
Miteva R. Comparative study of traumatic damage in the anogenital area in male and female victims of sexual violence	159




The State Medical and Pharmaceutical
University "Nicolae Testemițanu"
of the Republic of Moldova



ACTUAL ISSUES OF MORPHOLOGY
Materials of the International Scientific Conference
dedicated to the birth centenary of Professor B. Z. Perlin

PROBLEME ACTUALE ALE MORFOLOGIEI
Materialele Conferinței științifice internaționale
dedicată centenarului profesorului B.Z. Perlin

АКТУАЛЬНЫЕ ВОПРОСЫ МОРФОЛОГИИ
Труды Международной научной конференции
посв. 100-летию со дня рождения проф. Б.З. Перлина



20-22 of September, 2012

CZU: [611+611.013+611.018](063)

PROBLEME ACTUALE ALE MORFOLOGIEI. Materialele Conferinței științifice internaționale dedicată centenarului profesorului B.Z. Perlin (sub redacția Iliia Catereniuc). Ed.: Sirius SRL, Chișinău, 2012, 416 p.

Culegerea cuprinde articole științifice recenzate pe probleme actuale ale anatomiei, histologiei și embriologiei omului și animalelor, precum și materiale referitoare la organizarea procesului didactic și diferite forme de instruire și control la catedrele de profil morfologic a specialiștilor în domeniu din R. Moldova, R. Belarus, Ucraina, F. Rusă, Gruzia, Bulgaria, Israel, Romania, SUA. Materialele sunt destinate specialiștilor în morfologie și alte domenii ale medicinei.

Sub redacția:

Iliia Catereniuc, dr. habilitat în medicină, profesor universitar, prorector adjunct pentru activitatea științifică USMF
Nicolae Testemițanu

Recenzenți:

Natalia Cherdivarenko, dr. habilitat în medicină, profesor universitar, Om Emerit
Iliia Catereniuc, dr. habilitat în medicină, profesor universitar
Mihail Ștefanef, dr. habilitat în medicină, profesor universitar, Om Emerit
Ludmila Chiroșca, dr. habilitat în medicină, profesor universitar
Nicolae Frunțașu, dr. habilitat în medicină, profesor universitar
Tudor Lupașcu, dr., conferențiar universitar
Tamara Hacina, dr., conferențiar universitar
Viorel Nacu, dr. habilitat în medicină, profesor universitar

Redactori literari: *Valentina Bureatinscaia*,
Ludmila Covalschi

Descrierea CIP a Camerei Naționale a Cărții

“Probleme actuale ale morfologiei”, conf. șt., intern. (2012 ; Chișinău). “Probleme actuale ale morfologiei” :
Materialele Conf. Șt., Intern. : dedicată centenarului profesorului B. Z. Perlin, Chișinău, 20-23 sept. 2012. – Ch. :
S. n., 2012 (“Tipogr.-Sirius”). – 416 p.

Antetit.: Direcția Gen. Educație, Tineret și Sport. Univ. de Stat de Medicină și Farmacie “Nicolae Testemițanu”
din Rep. Moldova. – Texte: lb. rom., engl., rusă. – Bibliogr. la sfârșitul art. – 200 ex.

ISBN 978-9975-57-046-6.

612.01:616.83(092)(082)=135.1=111=161.1

P 93

ISBN 978-9975-57-046-6.

27. Unger F. Reply to "Ascending aortic fold or Rind eich's fold – an enigma". Clin. Anat. 2005;18: 396.
28. Verrier R.L. et al. The Enigmatic Cardiac Fat Pads: Critical but Underappreciated Neural Regulatory Sites. J. Cardiovasc. Electrophysiol. 2002; 13: 902-903.
29. Wesley W. Parke et al. Surgically relevant structure on the ascending aorta. Clin. Anat. 2004; 17: 159-160.
30. Wesley W. Parke et al. The human aortic ridge and cushion. The Anatom. Records. 1966;154; 1: 185-193, 1966.
31. White C. M. et al. Impact of epicardial anterior fat pad retention on postcardiothoracic surgery atrial fibrillation incidence. J. Am. Col. Cardiol. Fondat. 2007;49; 3:298-305.
32. White M.C. et al. Impact of Epicardial Anterior Fat Pad Retention on Postcardiothoracic Surgery Atrial Fibrillation Incidence. J. Am. Col. Cardiol. 2007;49; 3:298-303.
33. Zev Davis et al. Aortic Fat Pad Destruction and Post Operative Atrial Fibrillation. J.Card. Electrophysiol. Rev. 2003; 7; 2 :185-188.
34. Zev Davis et al. Retaining the Aortic Fat Pad during Cardiac Surgery decreases postoperative atrial fibrillation. Heart Surg. Forum. 2000; 3 (2): 108-112.

The features of research of the cerebrum of fetuses and newborns

*** V. V. Kolesnyk, I. Yu. Olijnyk**

Bukovinian State Medical University of Chernivtsi, Ukraine

*Corresponding author: E-mail: kurvatura@mail.ru

Особенности исследования головного мозга плодов и новорожденных

Авторы предлагают методологические подходы к изучению мозга плодов и новорожденных. Некоторые из них (оценка скорости гирификации и ее соответствия сроку гестации плода с помощью визуализации поверхности полушарий головного мозга; перфузии сосудов головного мозга фиксатором Караганова) оригинальные, информативны и могут успешно использоваться морфологами в их научной работе.

Ключевые слова: головной мозг, плоды, новорожденные, подходы исследования.

Actuality of the theme

According to the publications of scientific sources from the last five years, the cerebral pathology of fetuses and newborns represents a topical problem of modern health protection. This fact encourages researchers (morphologists) to carry out new scientific inquiries, as normal development of the brain may be disturbed under the influence of many factors, which is stipulated by both a high sensitivity of the brain during critical periods of development and by the irreversibility of some consequences of these effects. Extreme manifestations of the action of different pathogenic factors are defects of the development of an organ that are not compatible with life or result in a steady decrease of the intellectual ability or physical disabilities.

Mental disorders, diseases of the nervous system and the sense organs occupy a leading position in the pattern of diseases. Congenital malformations of the central nervous system of a fetus make up from 10% to 30% of the overall congenital pathology. Primarily, this belongs to anomalies of the ventricular system of the fetal brain [4].

A retrospective analysis of 1,542 records of children's dissections performed by I. Yu. Oliinyk, Yu. T. Akhtemiiichuk, Yu. I. Koval' et al. [7] at the Chernivtsi Regional municipal medical institution "Pathoanatomical bureau" during 2001 to 2008 has demonstrated that the total rate of congenital malformations in Bucovyna makes up 20.4%. Congenital malformations were detected in all age groups. The predominant majority of them consisted of children in the first year of life. Abnormalities of the system of blood circulation (33.0%), the nervous system (21.0%), and multiple congenital malformations (9.5%) predominated in the nosological pattern.

Material and methods

Using classical methodological training aids and our own experience, we propose a number of approaches to the pathomorphological research of the brain of fetuses and newborns.

Results and discussions

An essential growth of the total incidences of congenital malformations in Bucovyna over a period from 2007 to 2008 stipulated the inclusion of the fetus miscarriages, weighing 500g [7] into a statistical record. In

accordance with the report of V. P. Pishak et al. [9], congenital malformations rank third after perinatal causes and accident within the framework of mortality of children of the Chernivtsi region aged from 0 to 14 years. A recent study of the pattern of congenital malformations in Bukovyna's children in research done by Bukovinians authors [10] has shown that defects of the central nervous system (32.63%) are the most predominant.

The situation is not just territorial for Bukovyna, or Ukraine as a whole. Using an analysis of the level of children's disabilities in St. Petersburg (Russia), N. Yu. Yanushanets [12] asserts that diseases of the nervous system make up 21.4% of all the diseases that cause disabilities in childhood. Children's disabilities due to hydrocephaly according to the findings [3], is still higher and constitutes 36.3%. At the same time, about 50,000 disabled children are registered in Russia through the review process of a medicosocial expert commission of 16-year old adolescents.

An unfavourable situation, of our way of thinking, is partially the consequence of the imperfection of diagnosis, remedial and prophylactic measures. This dictates a task of in-depth and complex research of the brain of fetuses and newborns whose successful solution depends, to a certain extent, on the quality of the material and methodological approaches to the pathomorphological investigation of the brain.

The brain is carefully removed out of the cranial cavity in a complex with the cerebellum in the process of fetal and neonatal autopsy based on the method of Khrushchevsky-Sperl-Zeifridova [1] and with the view of further organometry [2] and is placed with the basal surface downwards on a preparation table. Using a caliper and a metal ruler, the linear parameters of the brain are measured with the accuracy up to 1mm: the length (the largest distance between the temporoparietal lobes of the right and left hemispheres of the brain), the height (the vertical distance between the highest point of the medial margin of the right or left cerebral hemisphere and the lowest point of the corresponding temporal lobe). The mass of the organ is determined with the accuracy of 1g. on an electronic balance. The volume of the organ is evaluated based on the amount of milliliters of the physiological solution, which the brain displaces from a graduated cylinder.

On the process of a macroscopic investigation of the brain of fetuses and newborns, it is important that the peculiar features of the relief of the surfaces of the cerebral hemispheres should be studied and macrophotographing should be documented. This particular research makes it possible to evaluate the tempo of relief formations on the surfaces of the cerebral hemispheres and its correspondence to the gestational age, which takes into account the fact that in case of an uncomplicated course of pregnancy, three stages are determined in the surface terrain formation of the cerebral hemispheres that is evaluated on the basis of the succession of the appearance of first order sulci [11]. The first is during weeks 20-21 of the intrauterine development (IUD). The sulci are present only on the medial surface of the hemispheres (the sulci-calcarine, parietooccipital, sulcus of the corpus callosum), while the convexital cerebral surface looks smooth. The second is during weeks 22-23 of IUD there occurs the formation of the principal sulcus of the first order, which enables the demarcate of the large hemispheres into portions. The third is during weeks 24-25 of IUD. The formation of all the sulci of the first order is completed. It is possible to discern the dyschronic development of the brain in fetuses and newborns by slowing down the tempo of gyrification during weeks 2-3 of IUD, because the formation of the cortical terrain of the hemispheres, at the expense of a successive appearance of first order sulci, prior to the beginning of the 20th week of gestation, is not completed.

The macroscopic method of visualization makes it possible to detect congenital malformations of the brain: prosencephaly (a group of malformations of the anterior cerebral vesicle), holoprosencephaly (the brain looks like a hemisphere with a single open ventricular cavity); atelencephalia (the absence of the large hemisphere and subcortical nuclei with a preserved cranium); macro-, microcephalia, microgyria, and polygyria (polymicrogyria-a cerebral malformation that is characterized by the presence of numerous tiny gyri and is manifested, as a rule, by mental retardation), pacygyria (a dilatation of the gyri of the cerebral large hemisphere and a decrease of the number of the cerebral sulci), agyria (a malformation with a slight marked character of the cortical gyri of the brain owing to a disturbed migration of neuroblasts in the embryogenesis), as well as a number of genic syndromes that declare themselves by multiple congenital malformations (agnosia-holoprosencephaliae, Dondy-Walker, Walker-Warburg, Patau, etc.) [6].

While working with the brain, without its fixation, there arise deformities of the organ structures. A qualitative fixation of the brain is achieved by its dipping, for a term of several 24-hour periods to two weeks, into a 10% neutral solution of formal with an addition of corrosive sublimate (10mg of mercury dichloride per 100 ml of a 10% solution of neutral formal). The brain fixed in this way acquires an elastic flexible consistency, which facilitates the performance of manipulations associated with a targeted study of the organ. With a view

of a prolonged fixation, the brain is submerged into a solution of neutral formal dissected into the halves in the horizontal plane at the level of the commissure of the fornix.

It is extremely important to perform autopsies within the next 2 hours upon the certification of clinical death. Early proper autopsies enable a qualitative material sampling for a bacteriological, bacterioscopic (smears - imprints from the pia maters and the ependymic lining of the lateral ventricles), immunofluorescent, and immunohistochemical investigations, thus avoiding artifacts at all the stages of material handling up to the preparation of histologic specimens and blocks for electron microscopy.

Material sampling should be carried out simultaneously for the whole complex of planned investigations. An evaluation of the material must be performed at different structural levels – organic, tissular, cellular, sub-cellular, and molecular, which enable the establishment of the dynamics of quantitative and qualitative changes in the object under study. Sampling of the material for a bacterioscopic and bacteriologic examination allows for the specification of the etiology of an inflammation. Smears – imprints from the pia mater of the brain of the cerebral basal surface and visually changed segments of the ventricular ependyma should be evaluated after staining specimens according to Gram [5, 8].

Taking the cerebral tissue for a histological analysis, using a survey and selective stainings [5], should be implemented in the anatomical portions of the brain, taking into account a projection on the elements of the ventricular system. The lateral fragment of the middle one third of the superior frontal sulcus corresponds to the anterior horns of the lateral ventricles; the medial fragment of the posterior one third of the said sulcus to the bodies; the posterior horns – the area of the lower parietal lobe which is bounded by the superior and the middle temporal fissures. An approach to the third ventricle located in the midsagittal plane and bounded by the medial surfaces of the thalami is realized under visual control following a preliminary performance of a horizontal section of the brain at the commissure of the fornix. The sylvian aqueduct is easily accessible for visualizing and research on transverse serial sections of the cerebral peduncles, the IVth ventricle – on a sagittal – medial section of the medulla oblongata.

One of the indispensable conditions of a complex morphologic research of the brain is a study of the histological characteristics of the vascular plexuses and the pia mater from the basal surface of the cerebral hemispheres, which takes a direct part in the production and absorption of the liquor. Upon fixing the brain in nature, formal pieces of the tissue are dissected from the above-mentioned anatomical segments of both hemispheres measuring 0.5 x 0.5 cm, including the cortex, the white substance, germinative matrix, and the ependymic lining. Paraffin sections, 18-20 mm thick are prepared from the fixed material, they are stained with Erih's hematoxylin with additional eosin staining, as well as a 0.5% solution of cresyl violet and thionine according to Nissl's method [5, 8] and are embedded in balsam.

The cyto- and angioarchitectones of the brain are studied based on survey specimens. The use of elective staining permits the detection of peculiar features of the structure of the cytoarchitectonic layers of the neocortex, the white substance, the germinative matrix, the ependyma, and their cellular elements.

Later, histostereometric (the thickness of the cerebral parenchyma, cytoarchitectonic layers, germinatives zones) and the cytokaryometric indices are calculated on survey specimens. They enable the evaluation of the degree of atrophy of the cerebral parenchyma, and also relations of the volume parameters of the nuclei of neurons, glial cells, and ependyma. The cytokaryometric index is computed according to K. Tashke, who used formulas depending on the form of a nucleus: $V = \pi/G \times (LB^2)$ or $V = \pi/6 \times D^3$, where:

- L - Larger diameter of a nucleus of an ellipsoid form;
- B - Smaller diameter of a nucleus of an ellipsoid form;
- D - The diameter of spherical cells.

For the purpose of studying the structural characteristics of the elements of the ventricular system and the cerebral parenchyma at the subcellular level, material sampling for electron microscopy should be performed during the first 20 minutes of the autopsy.

A qualitative fixation of the tissue may be achieved, using the method of perfusion of the cerebral vessels with the aid of Karavanov's fixation. Upon dissecting the thorax and mediastinum, 300-350 ml of 25% glutaraldehyde are introduced into the vascular system of a fetus (a newborn) via the left ventricle of the heart and the pressure of 20-30 mm of the mercury column during 10-15 min. It is necessary to create the outflow of blood from the lumen of the open right internal jugular vein to prevent an induced elevation of pressure in the vascular system, and, respectively the emergence of artifacts at the moment of perfusion pieces of the tissue, measuring 0.3 x 0.3 cm are excised from the above – mentioned zones of the cerebral parenchyma, which are dipped into 2% glutaraldehyde on the phosphate buffer (pH 7.3) for further fixation.

Findings

Thus, taking into account the organospecific features of the brain (soft, jelly-like consistency, the watery character) and the complexity of visualization of the liquor system associated with them, we propose some methodological approaches to a study of the brain of fetuses and newborns, which includes special methods of fixation and a complex evaluation of pathomorphologic changes at all levels of the structural organization. An evaluation of the rates of gyrification and their correspondence to the gestational age of a fetus or a newborn, a perfusion of the cerebral vessels with the aid of Karavanov's fixator are original, informative, and may be used successfully by morphologists in their research work.

References

1. Автандилов Г.Г. Основы патологоанатомической практики. Руководство (3 изд., дополненное) / Г.Г. Автандилов. – М.: РМАПО, 2007. – 480 с.
2. Автандилов Г.Г. Медицинская морфометрия / Г.Г. Автандилов. – М.: Медицина, 1990. – 382 с.
3. Барашнев Ю.И. Роль гипоксически-травматических повреждений головного мозга в формировании инвалидности с детства / Ю.И. Барашнев, А.В. Розанов, В.О. Панов [и др.] // Рос. вестн. перинат. и педиатрии. – 2006. – Т. 51, № 4. – С. 41-46.
4. Волков А.Е. Пренатальная диагностика редких пороков центральной нервной системы / А.Е. Волков // Пренатальная диагностика. – 2005. – Т. 4, № 3. – С. 179-185.
5. Волкова О.В. Основы гистологии с гистологической техникой / О.В. Волкова, Ю.К. Елецкий. – М.: Медицина, 1982. – 304 с. 6. Лазюк Г.И. Тератология человека / [Лазюк Г.И., Кириллова И.А., Кравцова Г.И., Кручинский Г.В. и др.]; под ред. Г.И. Лазюка. – М.: Медицина, 1991. – 480 с.
7. Олійник І.Ю. Структура природжених вад на Буковині у 2001-2008 рр. / І.Ю. Олійник, Ю.Т. Ахтемійчук, Ю.І. Коваль [та ін.] // Вісник морфології. – 2008. – Т. 14, № 2. – С. 415-418.
8. Олійник І.Ю. Методичні основи гістопатологічних і гістохімічних досліджень / І.Ю. Олійник. – Чернівці, 2001. – 73 с.
9. Пішак В.П. Епідеміологія уроджених вад розвитку в дітей Буковини / В.П. Пішак, М.О. Ризничук, В.Г. Остапчук // Здорова дитина: основи раціонального харчування: матер. VI наук.-практ. інтернет-конференції з міжнарод. участю (18 лютого 2011 р.). – Чернівці: БУКМЕА, 2011. – С. 65. 10. Пішак В.П. Частота та структура уроджених вад розвитку в дітей Чернівецької області / В.П. Пішак, М.О. Ризничук, В.Г. Остапчук // Здорова дитина: основи раціонального харчування: матер. VI наук.-практ. інтернет-конференції з міжнарод. участю (18 лютого 2011 р.). – Чернівці: БУКМЕА, 2011. – С. 64-65.
11. Проценко Е.В. Особенности формирования рельефа коры полушарий большого мозга у новорожденных с экстремально низкой массой тела при физиологическом течении и невынашивании беременности / Е.В. Проценко, Л.П. Перетятко, Н.А. Миронычева // Архив патологии. – 1996. – Вып. 1. – С. 51-54.
12. Янушанец Н.Ю. Анализ уровня и структуры детской инвалидности вследствие заболеваний нервной системы в Санкт-Петербурге / Н.Ю. Янушанец // Рос. вестн. перинат. и педиатрии. – 2006. – Т. 51, № 4. – С. 53-56.

Morphofunctional changes in the structure of rats' adrenal glands cortex zones by alcohol intoxication and the effect of antioxidant

*A. G. Kvaratskheliya, S. N. Semyonov, S. O. Fetisov, N. N. Voronezh

Burdenko State Medical Academy of Voronezh, Voronezh, Russia

*Corresponding author: E-mail: anna_kvar_83@mail.ru

Studies have shown that prolonged involuntary alcohol intoxication causes significant structural and functional reorganization of the cortex of the adrenal glands. Natural antioxidant α -tocopherol has a modifying influence on changes in the cells of the adrenal glands cortex in case of alcoholization, with the intensity and direction of this effect depends on whether the use of alcohol is being continued.

Key words: the cortex of adrenal glands of rats, alcohol, antioxidant.

Морфофункциональные изменения в структуре зон коры надпочечников крыс под влиянием алкогольной интоксикации и антиоксиданта

Исследования показали, что длительная непроизвольная алкогольная интоксикация приводит к значительной структурной и функциональной реорганизации коры надпочечников. Природный антиоксидант α -токоферол имеет модифицирующее влияние на изменения в клетках коры надпочечников железы в случае алкоголизации, интенсивность и направленность этого влияния зависит от того, продолжается ли употребление алкоголя.

Ключевые слова: кора надпочечников крыс, алкоголь, антиоксидант.