

N.I. Yaremchuk, A.P. Oshurko, I.Yu. Olijnyk, L.M. Herasym, V.O. Student¹
Bukovinian State Medical University, Chernivtsi,
¹Center for medical 3D diagnostics, Lviv

**MORPHO-, DENSITOMETRIC ANALYSIS OF THE DYNAMIC VARIABILITY
OF BONE TISSUE OF THE CORONOID PROCESSES OF THE HUMAN MANDIBLE,
DEPENDING ON THE LOSS OF THE MASTICATORY GROUP OF TEETH**

e-mail: olijnyk1961@gmail.com

The purpose of the study was to establish morphological variability of the macro- and microstructure of the bone tissue of the coronoid processes of the human mandible depending on the loss of the masticatory group of teeth in the I and II age periods of postnatal ontogenesis. The method of computed tomography with the Ez3D-i software (5.1) was used to study qualitatively homogeneous totals – quantitative indicators that determine the morphometric values and density of bone tissue in conventional gray units, a detailed analysis of the structure of the bone tissue of the coronoid processes of the left and right sides (n=136). The results of the study present quantitative morphometric values in individuals with limited and final dentition defects obtained in the areas of the coronoid processes exposed to the primary multifactorial pathoetiological influence, which have a negative direction on both sides when compared between the I and II age periods. In the case of acquired terminal defects of the dentition, the morphometric values of the base of the coronoid processes increase and are synchronized with the comparison group (mandibular angle quadrant). However, the densitometric variability of the bone tissue of the coronoid processes of the human mandible does not have a stable upward or downward trend.

Key words: bone atrophy, lower jaw, coronoid processes, computed tomography.

**Н.І. Яремчук, А.П. Ошурко, І.Ю. Олійник, Л.М. Герасим, В.О. Студент
МОРФО-, ДЕНСИТОМЕТРИЧНИЙ АНАЛІЗ ДИНАМІЧНОЇ МІНЛИВОСТІ КІСТКОВОЇ
ТКАНИНИ ВІНЦЕВИХ ВІДРОСТКІВ НИЖНЬОЇ ЩЕЛЕПИ ЛЮДИНИ,
ЗАЛЕЖНО ВІД ВТРАТИ ЖУВАЛЬНОЇ ГРУПИ ЗУБІВ**

Дослідження присвячено вивченню морфологічної мінливості макро- та мікроструктури кісткової тканини вінцевих відростків нижньої щелепи людини залежно від втрати жувальної групи зубів у I та II вікових періодах постнатального онтогенезу. Методом комп'ютерної томографії із програмним забезпеченням Ez3D-i (5.1) вивчені якісно однорідні сукупності – кількісні показники, що визначають морфометричні значення та щільність кісткової тканини в умовних одиницях сірості, проведено деталізований аналіз структури кісткової тканини вінцевих відростків лівої та правої сторін (n=136). У результатах дослідження подаються кількісні морфометричні значення в осіб при обмежених та кінцевих дефектах зубного ряду, що отримані на ділянках вінцевих відростків, які піддаються першочерговому мультифакторному патоетіологічному впливу, мають від'ємне спрямування з обох сторін при порівнянні між I та II віковими періодами. При набутих кінцевих дефектах зубного ряду морфометричні значення ділянки основи вінцевих відростків зростають та є синхронними із групою співставлення (квадрант кута нижньої щелепи). Проте, денситометрична мінливість кісткової тканини вінцевих відростків нижньої щелепи людини не має стійкої динаміки у сторону зростання чи зниження.

Ключові слова: атрофія кісткової тканини, нижня щелепа, вінцеві відростки, комп'ютерна томографія.

The study is a fragment of the research project "Structural and functional features of tissues and organs in ontogenesis, patterns of variant, constitutional, gender, age and comparative human morphology", state registration No. 0121U110121.

Updates of the available results of the study of the coronoid processes of the human mandible are insufficient and mostly remain outside the scope of scientific discussions. Brief morphological descriptions are often found in the study of the temporomandibular joint [13, 15] or the posterior group of masticatory muscles. However, with the development of reconstructive surgery [5], as an indirect requirement of martial law in our country, there has been an increase in the demand for understanding the anatomical variability of not only the macrostructure but also the structure of bone tissue [2, 3], which depends on the influence of factors that ensure its mineralization [4].

We are aware of historical descriptions of clinical cases by Pancoast and Kronlein (1936), who described surgical approaches to the pterygopalatine fossa with recommendations for osteotomy of the coronoid processes and their improvement by the authors (Fetisov M.V., 1954; Malanchuk V.O. et al., 2001), which are still relevant today. However, ensuring the further function of the coronoid processes still requires details regarding bone density, primarily as the regenerative potential of bone marrow and the corresponding morphological variability, which depends on the loss of the masticatory group of teeth. After all, clinical miscalculations will lead to an acquired pathology of the destructive and dysfunctional genesis of the temporomandibular tissue complex.

A significant role in deepening this "vicious circle" is played by the temporal muscles, which start from the entire plane of the temporal fossa (parietal bone line, temporal bone scales, temporal surface of

the frontal bone), uniting in two bundles to form the tendon that attaches to the coronoid process of the mandible. Such a distribution of functional strength will be reflected, first of all, in the morphological architecture of the coronoid processes, and the loss of the masticatory function of the teeth leads to a violation of the physiological function of its posterior bundles – a displacement of the mandible to the back.

In response to this request, we submit a study that details the morphometric and densitometric analysis of the dynamic variability of bone tissue of the human mandible's coronoid processes in areas primarily affected by pathoetiological factors of the internal and external environments.

The purpose of the study was to analyze the dynamic variability of bone tissue of the coronoid processes of the human mandible, depending on the loss of the masticatory group of teeth in the I and II age periods of postnatal ontogenesis, confirming the interpretation of the obtained morphometric and densitometric values.

Materials and methods. We selected 136 computed tomographic records of temporomandibular area examination with the image of the coronoid process of the human mandible from the database of 18689 clinical trials of the Center for Medical 3D Diagnostics LLC (legal entity identification number: 41907653, location: 18 Chernihivska St., Lviv, 79010, Ukraine). The selection of the study material was carried out in accordance with the current Agreement No. 2 on scientific cooperation between Bukovinian State Medical University (58002, Chernivtsi, Teatralna Square, 2, Ukraine) and the Center for Medical 3D Diagnostics of 02.10.2020. The ability to conduct a quick, detailed analysis of the bone structure of the coronoid processes of the mandible on the left and right sides, in particular, its density, in a minimally invasive and ergonomic way, was provided by the availability of digital methods of morphological research, namely the method of densitometric analysis using extraoral scanning Vatech PaX-i3D Green CT (PHT-60 CFO) with an ultra-sensitive radiation detector, an available set of functions (orthopantomography, tomography, teleradiography, examination of the temporomandibular area with an open/closed mouth) and an additional MAR module to reduce the number of artifacts from overlaps and inclusions (Fig. 1), with Ez3D-i software (5.1).

Computed Tomography digital scans were analyzed using Hewlett-Packard Z4 G4 Workstation computer equipment with an Intel Xeon W-2104 central processor, an Nvidia GeForce GTX 1660 GPU, 32 GB of RAM, and Windows 10 Pro for Workstations software (version 1903, product code 00391-70000-00000-AA381).

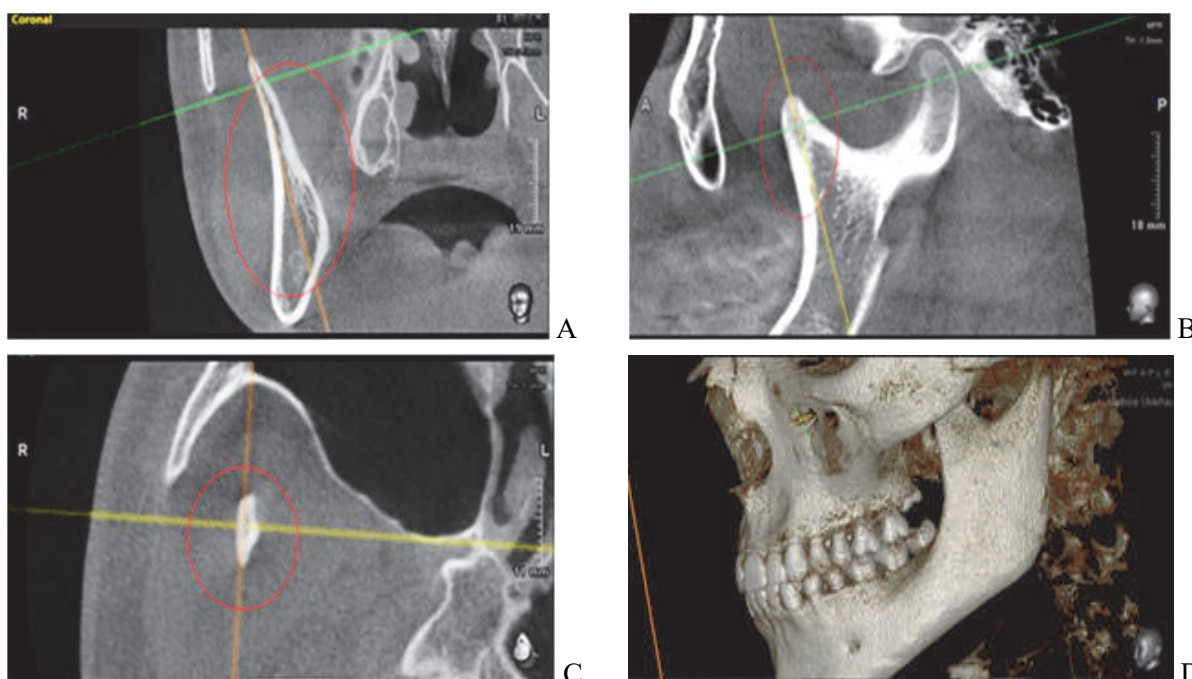


Fig. 1. Settings: A, B, C – in the coronal, sagittal, and axial planes (optional windows), the sagittal axis is set along the vertical axis of the coronoid process, centered perpendicularly and medially to its macrostructure; D – position of the 3D reconstruction model of the facial skull, from the left side, during the study of the coronoid process.

The method of statistical selection was used to distribute the study material by age for two periods (I–II) of adulthood of postnatal human ontogenesis (I-st period of adulthood – men aged 22–35 years, women aged 21–35 years; II-nd period – men aged 36–60 years, women aged 36–55 years). Depending on the pathoetiological factor, the selected material was distributed according to the degree of acquisition of a defect in the dentition of the lower jaw (LJ) by patients into three groups, namely: the first group – limited dentition defect, the second group is an existing final defect, the third group is individuals with preserved dentition, the control group.

For the morphometric study and determination of bone density, we chose quadrants that were primarily subjected to remodeling processes or pathological changes (Fig. 2), in particular:

- U-Ch/Q1 – upper cephalic quadrant of the coronoid process of the LJ (mean value of the density of the cortical layer of bone tissue);
- Mc/Q : P-Ln/Q3 – anterior-posterior quadrant of the neck of the coronoid process of the LJ (Mc/Q – mean bone density index; P-Ln/Q3 – the distance between the outer contours of the cortical layer of the bone tissue of the process);
- M-Ib/Q : P-Lb/Q – anterior-posterior quadrant of the base of the LJ process (M-Ib/Q – average bone tissue density index; P-Lb/Q – the distance between the outer contours of the cortical layer of the bone tissue of the process);
- c/g – control group, quadrant of the mandibular angle.

When conducting medical research, it is often necessary to use statistical analysis methods of data presented in semi-quantitative, semi-qualitative, and qualitative forms, which forces us to direct our choice to use nonparametric evaluation criteria.

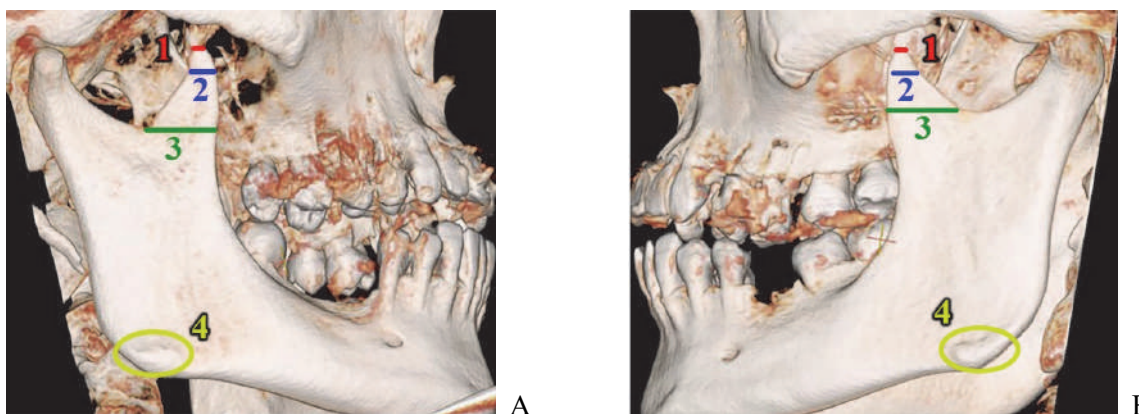


Fig. 2. Marking of the studied anatomical areas of the coronoid process (A – right side; B – left side) corresponding to the quadrants: 1 – U-Ch/Q1; 2 – Mc/Q:P-Ln/Q3; 3 – M-Ib/Q:P-Lb/Q; 4 – c/g.

Digital statistical analysis of the bone density of the coronoid processes of the lower jaw, depending on the loss of the masticatory teeth, presented as $M \pm \sigma$ (mean value and standard deviation). Using nonparametric statistical analysis methods, we compared the experimental groups with the control group using the Mann-Whitney U test.

Comparison of groups with each other – using the multidimensional Kruskal–Wallis test as an alternative intergroup analysis of variance, which compares three or more samples to test null hypotheses according to which different samples were taken from the same distribution with similar medians. The obtained differences between the groups were considered reliable as the change in the density of bone tissue has a multifactorial patho-etiological dependence described in this paper.

All the studies were conducted after patients familiarized themselves with and signed informed consent to participate in research in compliance with the main provisions of the GCP (1996), the Council of Europe Convention on Human Rights and Biomedicine (dated 04.04.1997), the World Medical Association Declaration of Helsinki on ethical principles for conducting scientific medical research involving human subjects (1964–2013), order of the Ministry of Health of Ukraine No. 690 dated 23.09.2009 № 616 dated 03.08.2012.

Results of the study and their discussion. The morphometric values of the most vulnerable morphological structure – the cervical region of the coronoid processes, which we present in Tables 1–2 (marking – P-Ln/Q3) attract attention by their pronounced variability, with limited dentition defects on the right side in comparison between the first and second adulthood periods of postnatal ontogenesis, in the direction of their decrease from 11.8 ± 1.487 mm to 6.309 ± 1.240 mm. A moderate downward trend is observed on the left side from 6.792 ± 1.011 to 6.709 ± 1.409 mm. In the case of final dentition defects, they also decrease both on the right side from 7.288 ± 1.690 mm to 7.008 ± 1.148 mm and on the left side from 7.488 ± 1.137 mm to 6.427 ± 0.760 mm between the first and second adulthood periods. The same dynamics of morphometric age-related variability is observed in the studied area of the base of the coronoid processes (marking in the tables – P-Lb/Q4). In the case of acquired terminal dentition defects, the morphometric values obtained during the study of the base of the coronoid processes tend to grow, with a slight opposite deviation in the first adulthood on the right side.

The densitometric variability of the bone tissue of the coronoid processes of the mandible does not have stable dynamics either in the direction of growth or vice versa in comparison between the study groups

of both age periods. After all, bone density is influenced by multifactorial patho-etiological factors, particularly changes in the functional state of the masticatory muscles and atrophy of the jaw bone tissue caused by the loss of the masticatory group of teeth.

Table 1

Results of *quantitative and qualitative indices that determine the morphometric values and density (GCU) of the bone tissue of the coronoid processes of the mandible on the right (R) and left (L) sides, the first age period of postnatal ontogenesis, due to partial/complete loss of the lateral/masticatory group of teeth, n= 34.

Marking	Study areas	Sides of the jaw	Control group (preserved dentition)	Limited dentition defect	Final dentition defect	p1	p2	p3
			M ± σ	M ± σ	M ± σ			
	n	R / L	13	13	8			
U-Ch/Q1	SD (cort.)	R	1645±531.7	1759±438.1	1525±272.0	0.131	0.772	0.219
		L	1806±440.9	1706±423.6	1748±415.9	0.626	1.000	0.664
Mc/Q : P-Ln/Q3	SD	R	1738±344.4	1776±476.7	1686±246.4	0.858	0.772	0.772
		L	1874±452.9	1947±371.5	1934±232.1	0.522	0.469	0.885
	M	R	7.692±1.376	11.8±1.487	7.288±1.690	0.701	0.405	0.515
		L	7.815±1.532	6.792±1.011	7.488±1.137	0.096	0.800	0.158
M-Ib/Q : P-Lb/Q4	SD	R	1783±316.5	1779±512.6	1481±602.4	0.898	0.311	0.515
		L	1793±378.8	1895±353.9	1801±213.6	0.626	0.247	0.942
	M	R	13.22±2.618	12.01±2.090	11.98±1.069	0.293	0.426	0.971
		L	13.52±2.249	11.64±2.058	11.91±1.776	0.073	0.129	0.971
c/g	SD (cort.)	R	2313±806.2	2490±615.8	2108±440.9	0.305	0.942	0.278
		L	2227±667.5	2348±523.6	2152±319.2	0.293	0.800	0.311

* Notes: SD (cort.) – densitometric values; M – morphometric values; p1 – comparison: Control group (preserved dentition) with a limited dentition defect; p2 – comparison: Control group (preserved dentition) with a final dentition defect; p3 – comparison: limited dentition defect with final dentition defect.

Table 2

Results of *quantitative and qualitative indices that determine the morphometric values and density (GCU) of the bone tissue of the coronoid processes of the mandible on the right (R) and left (L), the second age period of postnatal ontogenesis, due to partial/complete loss of the lateral/masticatory group of teeth, n= 34.

Marking	Research areas	Sides of the jaw	Control group (preserved dentition)	Limited dentition defect	Final dentition defect	p1	p2	p3
			M ± σ	M ± σ	M ± σ			
	n	R / L	11	11	12			
U-Ch/Q1	SD (cort.)	R	1500±386.4	1749±224.8	1656±282.6	0.212	0.325	0.580
		L	1625±290.4	1570±407.7	1795±291.9	0.870	0.094	0.189
Mc/Q : P-Ln/Q3	SD	R	1724±353.9	1716±303.4	1680±230.9	0.870	0.623	1.000
		L	1839±349.3	1661±324.8	1859±362.8	0.577	0.376	0.168
	M	R	7.509±1.486	6.309±1.240	7.008±1.148	0.049	0.325	0.243
		L	6.991±1.143	6.709±1.409	6.427±0.760	0.577	0.376	0.622
M-Ib/Q : P-Lb/Q4	SD	R	1629±313.3	1676±328.9	1619±242.5	0.718	0.878	0.712
		L	1635±261.5	1524±310.9	1776±390.8	0.341	0.356	0.157
	M	R	13.07±3.143	10.90±2.361	11.78±2.024	0.108	0.296	0.406
		L	12.43±1.936	11.22±1.741	11.33±1.632	0.179	0.196	0.735
c/g	SD (cort.)	R	2122±562.3	1926±230.9	2028±349.0	0.491	0.902	0.296
		L	12.43±1.936	1873±251.9	2133±334.3	0.123	0.623	0.027

* Notes: SD (cort.) – densitometric values; M – morphometric values; p1 – comparison: Control group (preserved dentition) with a limited dentition defect; p2 – comparison: Control group (preserved dentition) with a final dentition defect; p3 – comparison: limited dentition defect with final dentition defect.

However, in the comparison group, the most stable morphological structures – the angle of the mandible on the left and right sides, densitometric assessment emphasizes the above effect on the dynamics of bone density change (GCU) in the direction of decrease. With limited dentition defects in the first mature age period on the right side, the value of the dentition is 2490±615.8 GCU and rapidly decreases to 2108±440.9 GCU with final dentition defects. The same dynamics characterizes the bone density of the mandibular angle on the left side and amount to 2348±523.6 GCU in people with limited dentition defects, decreasing to 2152±319.2 GCU in acquired final dentition defects. The densitometric analysis shows the reverse dynamics of bone density in the second adulthood period of postnatal ontogenesis, increasing from 1926±230.9 GCU in limited dentition defects to 2028±349.0 GCU in terminal dentition defects on the right side and from 1873±251.9 GCU in limited dentition defects to 2133±334.3 GCU in terminal dentition defects on the left side of the mandibular angle.

The range of intergroup reliability, i.e., differences between comparison groups p1, p2, p3 concerning the constant coefficient $p < 0.5$, indicates the formation of dependence of morphometric values and bone density of the coronoid processes on multifactorial pathoetiological effects, in particular, the time of its manifestation and spread to the mandible, as the basis of the human masticatory system.

Modern scientific sources do not present the work of individual scientific studies that would detail the study of the coronoid processes of the mandible as a separate morphological structure that performs an essential functional role in the human masticatory system. Most authors consider the coronoid processes in the context of basic research, particularly when describing mandibular fractures [1, 7, 10] or acquired temporomandibular disorders as a consequence of their complications [9, 11]. The study of coronoid processes in the research of the results of functional hardware treatment of mandibular fractures in childhood [12] is neglected, which further leads to orthodontic pathology, pathological tooth abrasion [8] or tooth loss with the development of a cascade of pathological bone processes in adulthood [3], again placing scientific focus only on studies of the temporomandibular joint complex [6] or soft tissue damage associated with fractures of its coronoid processes [14]. After all, the attachment zones based on the branch and the anatomical (clinical) neck of both mandibular processes are often used for osteosynthesis using titanium plates. Morpho-, densitometric understanding of the architectonics of the coronoid processes is also required for the proper distribution of the force of intraoral instrumental action during odontological treatment, not only on the masticatory muscles but also, first of all, on the places of their jaw attachment, which determines the directed and desired morphological reconstruction. Otherwise, the angle of deployment and inclination of the coronoid processes will change due to the pathoetiological factor, particularly the loss of masticatory teeth, and will continue to form depending on the acquired mechanism of action of the masticatory muscles. This mechanism will affect the morphometric values and changes in the mineralization of the bone tissue of the coronoid processes of the mandible, causing a constant adaptive adjustment to new functional conditions of the body [4]. We have presented a detailed morphometric analysis and investigated the bone density of the most vulnerable zones of the coronoid processes of the human mandible in both adult age groups, with the loss of the masticatory group of teeth, which will be the basis for further scientific discussions and clinical differentiation in the selection of appropriate minimally invasive methods of rehabilitation of dental patients.

Conclusion

The most significant morphometric variability of bone tissue is observed in the cervical area of the coronoid processes on the right side and with a moderate decrease in morphometric values on the left side, with limited (included) dentition defects. 2. In the case of final dentition defects, the morphometric values of the coronoid processes decrease both on the right side – from 7.288 ± 1.690 mm to 7.008 ± 1.148 mm, and on the left side – from 7.488 ± 1.137 mm to 6.427 ± 0.760 mm in comparison between the first and second adulthood periods of postnatal ontogenesis. 3. Morphometric values in the area of the base of the coronoid processes increase in acquired terminal dentition defects. 4. The densitometric variability of the bone tissue of the coronoid processes of the mandible does not have a stable growth or decline.

Prospects for further research. The prospect of further research based on the obtained results is to study the interrelated mechanisms of the influence of the masticatory muscles, particularly the temporalis muscles, and the loss of occlusal relations on the morphological and histological variability of the coronoid processes of the mandible.

References

1. Brechlychuk PP, Goncharuk-Khomyn MYu. Otsinka skladovykh paterna perelomu nyzhnyoyi shchelepy za danymy retrospektyvnykh doslidzhen iz velykym obsiahom vybirok. Klinichna stomatolohiya. 2019; (1) :11–8. <https://doi.org/10.11603/2311-9624.2019.1.10142>. [in Ukrainian]
2. Malanchuk VA, Hryhorovskiy VV, Huseinov AN. Histolohichni zminy i koreliatsiyni zalezhnosti morfologichnykh pokaznykiv urazhennia ta reparatsiyi u kistkovykh ulamkiv pry ulamkovykh perelomakh nyzhnyoyi shchelepy. Visnyk stomatolohiyi. 2020; 113(4) :63–72. <https://doi.org/10.35220/2078-8916-2020-38-4-63-72>. [in Ukrainian]
3. Oshurko AP, Oliinyk IYu, Kuzniak NB, Holovatskyi AS. Porivnyalnyy analiz densytometrychnoho vyznachennya kistkovoyi tkanyny pry vtrati zhuvalnykh zubiv nyzhnoyi shchelepy. Klinichna anatomiia ta operatyvna khirurgiia. 2022; (1) :26–32. doi: 10.24061/1727-0847.21.1.2022.05. [in Ukrainian]
4. Oshurko AP, Oliinyk IYu, Kuzniak NB, Yaremchuk NI, Makarchuk IS. Znachennia morfometrychnoho doslidzhennia dlia vyznachennia minlyvosti topografichnykh spivvidnoshen struktur nyzhnoi shchelepy na prykladi sahitalnoho zrizu yii kuta. Klinichna ta eksperymentalna patolohiia. 2021; 4(78) :58–65. doi:10.24061/1727-4338. XX.4.78.2021.7. [in Ukrainian]
5. Pavlychuk TO, Chepurnyi YuV, Kopchak AV. Klinichna efektyvnist khirurgichnoho likuvannia perelomiv holivky nyzhnoi shchelepy i z vykorystanniam navihatsiinykh shabloniv ta patsiiento-spetsyfichnykh implantativ. Visnyk stomatolohii. 2020; 112(3) :41–49. <https://doi.org/10.35220/2078-8916-2020-37-3-41-49>. [in Ukrainian]
6. Pohranychna KhR. Diahnostychno-znachennia predyktoriv tkannyoi destruktivnoy skronevo-nyzhnoshchelepnoho suhloba pry travmatychnykh perelomakh suhlobovoho vidrostka nyzhnoi shchelepy. Klinichna stomatolohiia. 2021; (1) :20–27. <https://doi.org/10.11603/2311-9624.2021.1.12035>. [in Ukrainian]
7. Polishchuk SC, Skyba VIa, Polishchuk VS, Shuvalov SM, Polishchuk OO, Dalishchuk AI. Chastota ta struktura perelomiv nyzhnyoyi shchelepy. Visnyk stomatolohii. 2021; 113(4) :53–60. <https://doi.org/10.35220/2078-8916-2020-38-4-53-60>. [in Ukrainian]
8. Shumynskiy YeV, Kopchak AV, Hurianov VH, Lyseiko NV, Doroshenko OM. Otsinka okliuziynykh spivvidnoshen ta zhuvalnoyi funktsiyi u patsiientiv iz perelomamy verkhnyoyi shchelepy metodom kompyuternoyi okliuziografii. Klinichna stomatolohiya. 2021; (3) :10–25. <https://doi.org/10.11603/2311-9624.2021.3.12460>. [in Ukrainian]

9. Skrypa OL. Chastota diahnostovanykh skronevo-nyzhnoshchelepnykh rozladiv u khvorykh iz perelomamy nyzhnyoyi shchelepy zalezho vid lokalizatsiyi ta viku. Klinichna stomatolohiya. 2019; (1) :33–9. <https://doi.org/10.11603/2311-9624.2019.1.10145>. [in Ukrainian].
10. Kannari L, Marttila E, Toivari M, Thorén H, Snäll J. Paediatric mandibular fracture-a diagnostic challenge? Int J Oral Maxillofac Surg. 2020; 49 (11) :1439–44. <https://doi.org/10.1016/j.ijom.2020.06.008>; PMID:32680807.
11. Ren R, Dai J, Zhi Y, Xie F. Comparison of temporomandibular joint function and morphology after surgical and non-surgical treatment in adult condylar head fractures. J Craniomaxillofac Surg. 2020; (48) :323–30. <https://www.ncbi.nlm.nih.gov/pubmed/32113881>. <https://doi.org/10.1016/j.jcms>.
12. Stähli C, Eliades T, Papageorgiou SN. Functional appliance treatment for mandibular fractures: A systematic review with meta-analyses. J Oral Rehabil. 2021; (48) :945–54. <https://doi.org/10.1111/joor.13178>; PMID:33963591 PMID: PMC8362118.
13. Vanpoecke J, Dubron K, Politis C. Condylar Fractures: An Argument for Conservative Treatment. Craniomaxillofac Trauma Reconstr. 2020 March; 13(1) :23–31. <https://doi.org/10.1177/1943387520902881>. PMID:32642028.
14. Weinberg FM, Speksnijder CM, Forouzanfar T. Articular soft tissue injuries associated with mandibular condyle fractures and the effects on oral function. Int J Oral Maxillofac Surg. 2019; 48 :746–58. <https://www.ncbi.nlm.nih.gov/pubmed/30773333>. <https://doi.org/10.1016/j.ijom.2019.01.025>.
15. Yaremchuk NI, Oshurko AP, Oliinyk IYu. Age assessment of the dynamics of morphological rearrangement of bone tissue of the articular processes of the human lower jaw depending on the loss of the masticatory teeth. Polski Merkuriusz Lekarski. 2023; LI(2) :120–7. PMID: 37254758. doi:10.36740/Merkur202302103.

Стаття надійшла 1.09.2022 р.

DOI 10.26724/2079-8334-2023-3-85-191-194

UDC 616.314.17-008:612.017.1

Yu.Yu. Yarov,¹ Yu.I. Silenko,² G.A. Yeroshenko,³ K.V. Shevchenko,⁴ A.S. Grygorenko⁵
 Donetsk National Medical University, Lyman
¹Poltava State Medical University, Poltava

DYNAMICS OF LOCAL IMMUNOLOGICAL INDICATORS ACCOMPANIED BY DIFFERENT TYPES OF REACTIVITY OF THE ORGANISM

e-mail: kaf.intern.stomat@ukr.net

The dynamics of local immunity in the oral fluid in patients with generalized periodontitis after surgery accompanied by normo-, hyper- and hyporeactivity of the body. It was revealed that tension of local (lysozyme, β -lysine, SIgA, IgA, IgG in the oral fluid) immunity with normalization by the end of observation is typical for patients with generalized periodontitis with normoreactivity of the body after surgery. In case of hyperreactivity the dysfunction of local immunity which is shown by the expressed fluctuations of level of lysozyme, β -lysine, secretory IgA, IgA and IgG in oral fluid with their imbalance by the end of supervision is defined. In case of hyporeactivity dysfunction of local immunity is observed that is shown by a later rise and rather low amplitude of changes of the investigated parameters.

Key words: generalized periodontitis, local immunity, body reactivity, postoperative period.

Ю.Ю. Яров, Ю.І. Силенко, Г.А. Єрошенко, К.В. Шевченко, А.С. Григоренко ДИНАМІКА ПОКАЗНИКІВ МІСЦЕВОГО ІМУНІТЕТУ ПРИ ГЕНЕРАЛІЗОВАНОМУ ПАРОДОНТИТІ НА ТЛІ РІЗНОЇ РЕАКТИВНОСТІ ОРГАНІЗМУ

Вивчена динаміка показників місцевого імунітету в ротовій рідині у хворих на генералізований пародонтит після проведеного хірургічного лікування на тлі нормо-, гіпер- та гіпореактивності організму. Встановили, що для хворих на генералізований пародонтит при нормореактивності організму після проведення хірургічного втручання характерним є напруження місцевого (за рівнем лізоциму, β -лізину, SIgA, IgA, IgG в ротовій рідині) імунітету з нормалізацією показників до кінця спостереження. При гіперреактивності визначається дисфункція місцевого імунітету, що проявляється вираженими коливаннями рівня лізоциму, β -лізину, секреторного IgA, IgA і IgG в ротовій рідині з їх дисбалансом до кінця спостережень. При гіпореактивності спостерігається дисфункція місцевого імунітету, що проявляється більш пізнім підйомом і порівняно низькою амплітудою змін досліджених параметрів.

Ключові слова: генералізований пародонтит, місцевий імунітет, реактивність організму, післяопераційний період.

The work is a fragment of the research project "Studying the Influence of Oral Fluid and Biofilm on the Development of Diseases of the Oral Cavity". State registration number 0121U107494.

Analyzing the possible causes and mechanisms of generalized periodontitis, taking into consideration modern ideas about inflammation as a dynamic self-regulatory system, researchers have shown that the transition of the pathological process to a prolonged chronic course is observed in case of dysfunction of cellular and humoral local immunity [7]. Neutrophils play a key role in the development of inflammation and destruction of periodontal tissues, as they are the first to respond to chemotactic factors from dental plaque, infiltrate a huge number of periodontal tissues and perform their main effector functions – chemotaxis, adhesion, phagocytosis, oxidation [8]. Monocyte-macrophage cells, as well as neutrophils, are actively involved in a specific immune response (presentation of antigens to lymphoid cells, secretion of interleukins and complement components).